



# Chenin Orthodontics

Stephen T. Chenin, DDS

David A. Chenin, DDS

[www.CheninOrthodontics.com](http://www.CheninOrthodontics.com)



Member  
American Association of  
Orthodontists

**invisalign®**

4306 So. Eastern Avenue • Las Vegas, Nevada 89119-6016 • (702) 735-1010 • Fax: (702) 735-6823

## Cosmetic Orthodontics & Invisalign

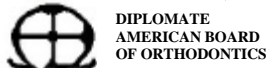
Thursday March 25, 2004

### Seminar Notes

- ❖ Stephen T. Chenin, D.D.S.
  - Board Licensed Orthodontic Specialist
  - Diplomat, American Board of Orthodontics
- ❖ David A. Chenin, D.D.S.
  - Manager of Clinical Process Development, Align Technology
  - Investigator, Invisalign ClinCheck Study, Univ. of Pacific Orthodontic Dept.
- ❖ Outline
  - Dr. David Chenin
    - Understand Case Selection
    - Advantages of Invisalign
    - Overview Technology & Software
    - Update on Research & Development
  - Dr. Stephen Chenin
    - Case Presentations
    - Discuss Other Cosmetic Orthodontic Appliances
- ❖ Invisalign Manufacturing Video
- ❖ What is Invisalign?
  - Aesthetic orthodontic treatment developed for adults and teens who can benefit from straight teeth
  - A series of clear, custom made, removable Aligners created to effectively move teeth into their desired position
  - Combines proven orthodontic science with 3-D computer graphics to project tooth movement.
- ❖ Invisalign Use
  - Aligners are worn 24 hours and removed for eating, drinking, brushing and flossing
  - Patients wear each set of Aligners in two-week intervals.
- ❖ Case Selection
  - Cases typically performed without the need for auxiliary appliances
    - Mild & Moderate Crowding
    - Mild & Moderate Spacing
    - Phase II Treatment / Orthodontic Relapse
    - Mild & Moderate Narrow Arches
    - Mild & Moderate Deep Bites
    - Combination Restorative Therapy
  - Cases typically requiring the need for auxiliary appliances
    - Crossbites
    - Sagittal Discrepancies (Class II, III)
    - Severe Deep Bites
    - Severely Narrow Arches
    - Severe Spacing
    - Severe Crowding
    - Openbites

Copyright 2004 Chenin Orthodontics, All Rights Reserved

Practice Limited Exclusively to Orthodontics and Dentofacial Orthopedics for both Children and Adults  
Cosmetic Orthodontic Treatment Available – Invisalign, Clear Braces, or Low Profile Gold / Silver Braces



# Chenin Orthodontics

Stephen T. Chenin, DDS

David A. Chenin, DDS

[www.CheninOrthodontics.com](http://www.CheninOrthodontics.com)



Member  
American Association of  
Orthodontists

**invisalign®**

4306 So. Eastern Avenue • Las Vegas, Nevada 89119-6016 • (702) 735-1010 • Fax: (702) 735-6823

## ➤ Case Studies

- Mild Crowding Case
  - Proclination and correction of deep bite
  - Chenin DA, Trosien AH, Fong PF, Miller RA, Lee RS. Orthodontic treatment with a series of removable appliances. J of Am Dent Assoc 2003; 134(9):1232-9.
- Moderate Spacing Case
- Deepbite Case
- Anterior teeth Edge-to-Edge Case
- Severe Crowding Case
  - Expansion and proclination.
  - Womack WR, Ahn JH, Ammari Z, Castillo A. A new approach to correction of crowding. Am J Orthod and Dentofac Orthop 2002; 133(3):310-316.
- Class II & Class III Cases
  - Posterior IPR to improve esthetics
- Restorative Veneer Case
  - Opened bite with Invisalign the veneered anterior
  - Norris RA, Brandt DJ, Crawford CH, Fallah M. Restorative and Invisalign: A New Approach. J Esthet Restor Dent 2002; 14(4):217-224.
- Implant Case
- Bicuspid Extraction Cases
  - Auxiliaries needed for these cases
  - Research cases shown
  - Boyd RL, Vlaskalic V. Three-dimensional diagnosis and orthodontic treatment of complex malocclusions with the Invisalign® Appliance. Semin Orthod 2001; 7(4): 274-293.

## ➤ Auxiliary Techniques

- What movements are less predictable?
  - Severe rotations of cylindrical teeth
  - Extrusion
  - Large Translation
- Achieving Less Predictable Movements
  - Severe rotations of cylindrical teeth
    - ◆ (*buttons & elastics*)
  - Extrusion
    - ◆ (*buttons & elastics*)
  - Large Translation
    - ◆ (*sectionals & archwire*)
- Same as traditional braces use of various auxiliary techniques for achieving specific movements
  - Positioners - Detailing Movements
  - Bite Planes - Intrusion / Extrusion
  - Palatal Expanders - Expansion
  - Magnets - Anchorage / Movements
  - Elastics - Sagittal & Vertical Movements
  - Springs - Midlines / Space Closure

Copyright 2004 Chenin Orthodontics, All Rights Reserved

---

Practice Limited Exclusively to Orthodontics and Dentofacial Orthopedics for both Children and Adults  
Cosmetic Orthodontic Treatment Available – Invisalign, Clear Braces, or Low Profile Gold / Silver Braces



# Chenin Orthodontics

Stephen T. Chenin, DDS

David A. Chenin, DDS

[www.CheninOrthodontics.com](http://www.CheninOrthodontics.com)



Member  
American Association of  
Orthodontists

**invisalign**<sup>®</sup>

**4306 So. Eastern Avenue • Las Vegas, Nevada 89119-6016 • (702) 735-1010 • Fax: (702) 735-6823**

- ❖ Invisalign Patient Advantages
  - Virtually invisible
  - Comfortable
  - Removable
  - Brush and floss normally
  - Less pain than traditional orthodontics
  - Patients can visualize their end result (ClinCheck®).
- ❖ Invisalign Clinical Advantages
  - Reduced risk of decalcification
  - Decreased occlusal abrasion from parafunctional habits during treatment
  - Ideal for positioning teeth for proper placement of restorations
  - Minimal additional instrumentation required
  - Visualization of Planned Tooth Movement (ClinCheck).
- ❖ Treatment Visualization Software ClinCheck<sup>™</sup>
  - Allows viewing of final outcome prior to treatment
  - Grid tools
  - Superimposition Tools
  - Ability to have different outcomes view 3D (extraction vs. non extraction)
- ❖ Publications
  - **34 Articles**
  - Journal of American Dental Association (JADA)
  - Compendium of Continuing Education in Dentistry
  - Journal of Esthetic and Restorative Dentistry
  - Journal of Clinical Orthodontics (JCO)
  - Seminars in Orthodontics
  - Etc.
- ❖ Research / Studies
  - Extremely difficult cases (University of the Pacific)
  - Speed and Materials (University of Washington)
  - Attachments (University of Florida)
  - Combination Treatment (University of Berlin)
  - 3-D Scanning (Internal)
  - Diagnosis & ClinCheck Study (University of the Pacific)
  - Various Topics (Private Practice Research)
- ❖ Teen Research
  - Preliminary findings from the Adolescent Treatment with the Invisalign Appliance study as of March 2003 have been compiled and are now available. Interim analysis indicates that: Invisalign is effective in the treatment of teens.
    - ANDY TROSIEN, DDS, MS, CHRIS PEARSON, UPDATE: EARLY TEEN STUDY DATA SHOWS EFFICACY, COMPLIANCE, Invisalign Clinical Update, Summer 2003.
  - Teens are compliant with Invisalign to achieve desired results
  - Oral hygiene is maintained in teen patients during treatment
  - Teens average wearing aligner for over 20 hours per day!
  - 2<sup>nd</sup> Molars must be fully erupted

Copyright 2004 Chenin Orthodontics, All Rights Reserved

Practice Limited Exclusively to Orthodontics and Dentofacial Orthopedics for both Children and Adults  
Cosmetic Orthodontic Treatment Available – Invisalign, Clear Braces, or Low Profile Gold / Silver Braces



# Chenin Orthodontics

Stephen T. Chenin, DDS

David A. Chenin, DDS

[www.CheninOrthodontics.com](http://www.CheninOrthodontics.com)



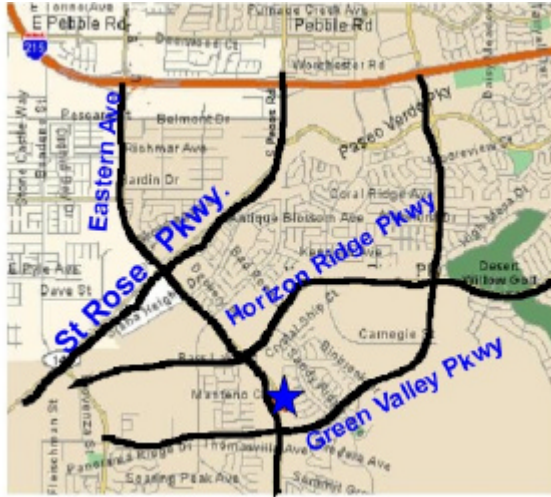Member  
American Association of  
Orthodontists



**4306 So. Eastern Avenue • Las Vegas, Nevada 89119-6016 • (702) 735-1010 • Fax: (702) 735-6823**

- ❖ [www.invisalignncec.com](http://www.invisalignncec.com)
- ❖ Clinical Support
  - Customer Service: 888-82-ALIGN
  - David A. Chenin, DDS: (408) 470-1290 [dchenin@aligntech.com](mailto:dchenin@aligntech.com)
  - Clinical Team: (408) 470-1400 [clincomm@aligntech.com](mailto:clincomm@aligntech.com)


- ❖ Second office Location: ~10700 S. Eastern



- ❖ Dr. Stephen T. Chenin Case Studies
  - Invisalign Case – Mild Upper Crowding
    - Pre-tx Records, ClinCheck, Final Records
    - Proclination of incisors
  - Invisalign Case – Severe Lower Crowding
    - Pre-tx Records, ClinCheck, Final Records
    - Lower incisor extraction
  - Invisalign Case – Severe Lower Crowding
    - Pre-tx Records, ClinCheck, Final Records
    - Lower incisor extraction
    - Anterior Corssbite
    - Use of auxiliary technique for upper lateral incisor
- ❖ Other Cosmetic Orthodontic Options
  - Lingual Braces
    - Tend to be irritating on lingual oral tissues and difficult to clean
    - Invisalign, followed by Clear Braces, then Low Profile Braces are preferred
  - Low Profile Metal Braces
  - Gold Braces vs Silver Braces
  - Clear Braces (e.g. Clarity)
  - Non-Surgical Case – Severe Upper & Lower Crowding
    - Pre-tx Records, ClinCheck, Final Records

Copyright 2004 Chenin Orthodontics, All Rights Reserved

Practice Limited Exclusively to Orthodontics and Dentofacial Orthopedics for both Children and Adults  
Cosmetic Orthodontic Treatment Available – Invisalign, Clear Braces, or Low Profile Gold / Silver Braces



# Chenin Orthodontics

Stephen T. Chenin, DDS

David A. Chenin, DDS

[www.CheninOrthodontics.com](http://www.CheninOrthodontics.com)



Member  
American Association of  
Orthodontists



**4306 So. Eastern Avenue • Las Vegas, Nevada 89119-6016 • (702) 735-1010 • Fax: (702) 735-6823**

- Bicuspid Extractions
  
- ❖ Early Treatment (also know as Interceptive Treatment or Phase I Treatment)
  - Age 7: the year to remember for orthodontics
  - Key benefit from parent's & patient's perspective
  - Many other benefits of identifying orthodontic problems early
  - Benefits
    - Benefits for patient with an indication for early treatment:
      - Influence jaw growth in a positive manner
      - Lower trauma risk for protruded incisors "bucked teeth"
      - Reduce harmful oral habits & Improve speech problems
      - Improve aesthetics and self-esteem
      - Simplify / shorten treatment of later orthodontics, if it is needed
      - Reduce likelihood of impacted permanent teeth
      - Preserve or gain space for erupting permanent teeth
  - Case Study of Early Treatment
    - Age 9 Lateral incisors flared
    - Phase I: ~9 months Removable  
Age 9½: Started Phase I  
Age 10½: Finished Phase I
    - No treatment : ~2 ½ years  
Age 10½: - 12¾: Growth Monitoring
    - Phase II: ~1½ year Braces  
Age 13: Start Phase II  
Age 14½: Finish Phase II
  
- ❖ Have Fun!!!!

Copyright 2004 Chenin Orthodontics, All Rights Reserved

Practice Limited Exclusively to Orthodontics and Dentofacial Orthopedics for both Children and Adults  
Cosmetic Orthodontic Treatment Available – Invisalign, Clear Braces, or Low Profile Gold / Silver Braces